

PANORAMIC IMAGING WITH OCTA

Thanks to a large field of view, panoramic imaging software can noninvasively display retinal features similar to those seen with dye-based angiography.

BY MANISH NAGPAL, MS, DO, FRCS(EDIN), AND RAKESH JUNEJA, MS



Optical coherence tomography (OCT) and fluorescein angiography (FA) are the two most commonly employed imaging tools to investigate clinical features and plan management for various retinal pathologies.

Whereas OCT allows morphologic and quantitative assessments, FA detects anatomic locations and leakage patterns. In certain conditions, either imaging mode can lead to discrepancies in the data yielded, and neither can provide details of deeper retinal capillary plexus or choroidal vasculature. These limitations significantly affect our ability to understand pathology and, consequently, to determine prognosis and management.¹

THE SKINNY ON OCTA

OCT angiography (OCTA) is a functional extension of OCT that works on the principle of *decorrelation*. It uses interferometric analysis of short-coherence-length light reflected from moving blood within the retina and choroid



AT A GLANCE

- OCTA software can scan a limited field of view in various sizes of cube based on examiner preference and on the location and size of pathology.
- Panoramic OCTA can mimic the findings of FA noninvasively and replicate them on each follow-up exam.
- Panoramic OCTA has enabled clinicians to replace FA and ICGA in certain situations, such as when contraindications exist, but further investigation is needed.

“ OCT angiography (OCTA) is a functional extension of OCT that works on the principle of *decorrelation*.

and calculates the variation over time of reflectance parameters (eg, amplitude or phase).² OCTA can generate 3-D maps of microvasculature flow pattern from retinal capillary plexus and choroidal vasculature, and its capabilities have enabled us to better understand, analyze, and treat a number of retinal pathologies.^{3,4}

OCTA imaging software generates images based on a voxel-by-voxel computation of decorrelation signal.⁵ In a chosen field of view, the software scans 256 voxels, with eight B-scans repeated at each voxel. Further, at each voxel the software performs 256 A-scans per B-scan, with a distance between B-scans of 10 μm . The number of B-scans performed per voxel and the number of A-scans per B-scan varies according to the software and the algorithm used. Algorithms incorporated into the software perform computations based on clusters of B-scans and generate flow patterns based on motion of erythrocytes within the vasculature. This results in the formation of en face images of retinal capillary network and choroidal vasculature at various levels.^{6,7}

Limits of Resolution

OCTA software can scan only a limited field of view in various sizes of cube based on examiner preference and on the location and size of pathology. The fields of view used most frequently are 3 mm x 3 mm and 6 mm x 6 mm. In

general, the smaller the size of the cube, the higher the resolution. Thus, a limitation of OCTA is decreased image resolution with larger fields of view.

Expanding the Field of View

The AngioScan OCT Angiography software on the RS-3000 Advance OCT (Nidek) allows clinicians to compose panoramic images with larger fields of view—12 x 9 mm, 9 x 9 mm, 6 x 6 mm, and 4.5 x 4.5 mm—providing, respectively, 40° x 30°, 30° x 30°, 20° x 20°, and 15° x 15° fields of view. In each of these sizes of fields of view, the software splits the scanning area into 3 x 3-mm cubes. The resolution obtained is therefore the same as that of an individual 3 x 3-mm cube provided by other software, but a larger field is simultaneously scanned at the same time.

The en face images obtained with OCTA allow clinicians to visualize individual retinal vascular plexuses and choriocapillaris.² The large fields of view provided by panoramic imaging software now enabled us to noninvasively capture features previously seen only with FA. Further, panoramic OCTA images offer several advantages over dye-based angiography, including being noninvasive, allowing 3-D analysis, and being repeatable on follow-up examinations.⁵

This article explores some of the uses of panoramic

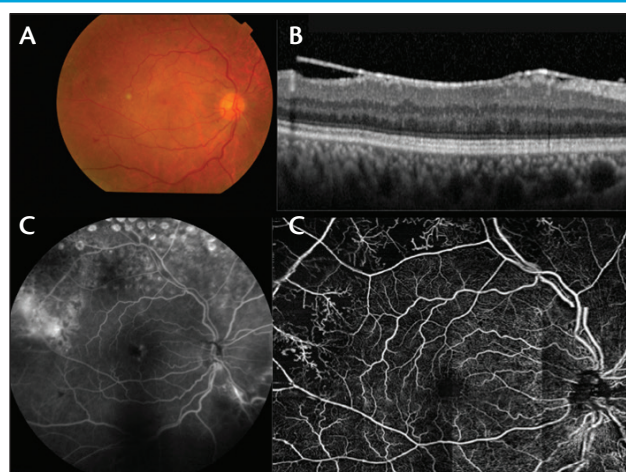


Figure 1. Fundus examination OD shows hemorrhage at the posterior pole and a few laser marks superotemporal to the FAZ (A). SD-OCT OD shows altered foveal contour with ERM and central foveal thickness (CFT) measuring 261 μm (B). FA OD shows normal FAZ, NVE around 1 DD temporal to the FAZ, focal leakage 0.5 DD inferonasal to the disc, and staining from laser marks (C). 12-x-9-mm panoramic OCTA OD shows a normal FAZ with well-demarcated architecture of vessels under the NVE (seen as leakage on FA) present 1 DD temporal to the FAZ and 0.5 DD inferonasal to the disc.

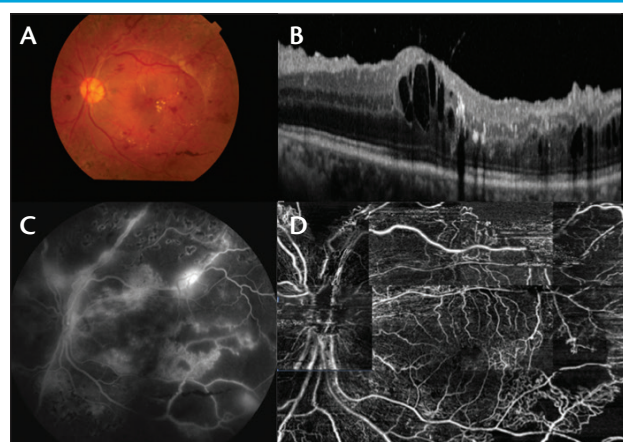


Figure 2. Fundus examination OS shows pale disc, lasered proliferative DR, and fibrous proliferation, causing traction threatening to involve the macula (A). SD-OCT OS shows altered foveal contour, cystoid spaces, and hard exudates, with CFT measuring 466 μm (B). FA OS shows altered FAZ, microaneurysms, NVD, NVE, and capillary nonperfusion areas at the posterior pole (C). 12-x-9-mm panoramic OCTA OS shows altered FAZ, which was obscured in FA, and a well-defined pattern and architectures of NVD and NVE at the posterior pole, signifying neovascularization and corresponding capillary nonperfusion areas at the posterior pole (D).

imaging software by comparing AngioScan OCT Angiography panoramic images with traditional FA images in a series of case reports.

OCTA PANORAMIC IMAGING VS. FA

The following is an observational case series of patients who presented at our practice. All patients were scanned using the AngioScan OCT Angiography software on the RS-3000 Advance OCT.

Case No. 1

A 55-year-old man with known hypertension presented with decreased visual acuity in his right eye (OD) lasting 2 months. His BCVA was 6/9 OD with early cataractous changes. Fundus examination revealed hemorrhage at the posterior pole around 1 disc diameter (DD) temporal to the foveal avascular zone (FAZ) and 0.5 DD inferonasal to the disc and laser marks superotemporal to the FAZ (Figure 1). Spectral-domain OCT (SD-OCT) showed an altered foveal contour OD and an epiretinal membrane (ERM), with central foveal thickness measuring 261 μm . FA revealed a normal FAZ OD, areas of leakage suggestive of neovascularization elsewhere (NVE) around 1 DD temporal to the FAZ, focal leakage 0.5 DD inferonasal to the disc, and staining from laser marks.

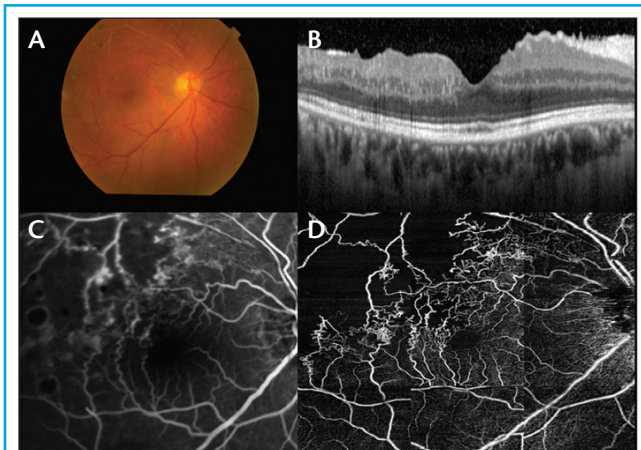


Figure 3. Fundus examination OD shows sclerosed blood vessels, laser marks, and collateral vessels (A). SD-OCT OD shows a maintained foveal contour with ERM and CFT measuring 238 μm (B). FA OD shows altered FAZ, staining of laser marks, and collateral vessels present superotemporal to the FAZ (C). 12-x-9-mm panoramic OCTA OD corresponding to FA shows altered FAZ with well demarcated architecture of collateral vessels present superotemporal to the FAZ (D).

Panoramic OCTA with a 12-x-9-mm field of view showed a normal FAZ, with well-demarcated architecture of vessels under the NVE (seen as leakage on FA) present 1 DD temporal to the FAZ and 0.5 DD inferonasal to the disc OD.

Case No. 2

A 48-year-old woman with known diabetes and hypertension presented with decreased visual acuity in her left eye (OS) lasting 4 months. Her BCVA was 6/9 OS with cataractous changes. Lasered proliferative diabetic retinopathy, a pale disc, and traction threatening the macula were noted on fundus examination OS (Figure 2). SD-OCT revealed altered foveal contour, cystoid spaces, and hard exudates, with central foveal thickness measuring 466 μm OS. FA revealed an altered FAZ, microaneurysms, neovascularization at the disc (NVD), NVE, and capillary nonperfusion at the posterior pole OS.

Panoramic OCTA with a 12-x-9-mm field of view OS showed a slightly altered FAZ, which was obscured on FA, and a well-defined pattern and architecture of NVD and NVE at the posterior pole, signifying neovascularization and capillary nonperfusion areas inferotemporal to the FAZ.

Case No. 3

A 56-year-old woman who was known to have hypertension presented with decreased visual acuity OD lasting 2 months. Her BCVA was 6/9 OD with early

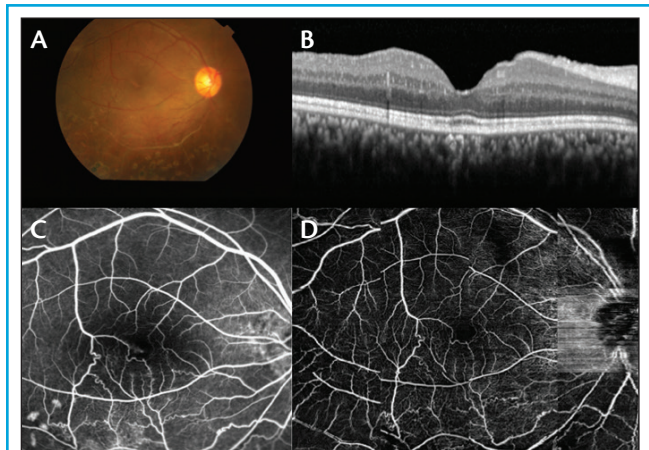


Figure 4. Fundus examination OD shows sclerosed blood vessels, laser marks, and collateral vessels near the macula (A). SD-OCT OD shows normal foveal contour, corrugation of inner retinal layers, and CFT measuring 238 μm (B). FA OD shows a normal FAZ, staining of laser marks, and collateral vessels present in the posterior pole near the FAZ (C). 12-x-9-mm panoramic OCTA OD corresponding to FA revealed a normal FAZ, clearly demarcated architecture of collateral vessels in the posterior pole near the FAZ, and a few laser marks inferiorly just below the arcade (D).

cataractous changes. Fundus examination revealed sclerosed blood vessels and laser marks with collateral vessels OD (Figure 3). SD-OCT revealed a maintained foveal contour and ERM with central foveal thickness measuring 238 μm OD. FA revealed altered FAZ, staining from laser marks, and collateral vessels present superotemporal to the FAZ OD.

Panoramic OCTA with a 12-x-9-mm field of view showed the altered FAZ and clearly demarcated architecture of collateral vessels present superotemporal to the FAZ OD.

Case No. 4

A 28-year-old man presented with decreased visual acuity OD lasting 2 months. His BCVA was 6/9 OD, and fundus examination revealed sclerosed blood vessels and laser marks with collateral vessels near the macula OD (Figure 4). SD-OCT revealed normal foveal contour, corrugation of inner retinal layers, and CFT measuring 238 μm OD. FA revealed a normal FAZ, staining from laser marks, and collateral vessels present in the posterior pole near the FAZ OD.

Panoramic OCTA with a 12-x-9-mm field of view showed a normal FAZ, clearly demarcated architecture of collateral vessels in the posterior pole near the FAZ, and a few laser marks inferiorly just below the arcade OD.

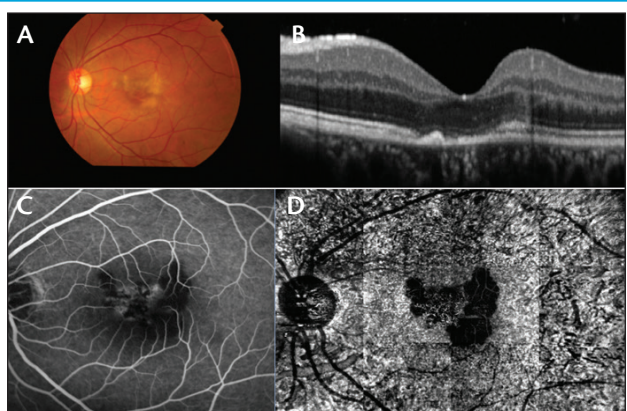


Figure 5. Fundus examination OS before treatment at the time of presentation reveals a subretinal yellowish scar at the fovea (A). SD-OCT OS before treatment at the time of presentation shows normal foveal contour, altered photoreceptor layer, a small pigment epithelial detachment (PED), and subfoveal and juxtafoveal scarring, with CFT measuring 188 μm (B). FA OS prior to treatment at presentation shows an altered FAZ and a hypofluorescent area in the foveal and juxtafoveal areas in early phase, which became hyperfluorescent in late phase, suggesting active choroiditis (C). 12-x-9-mm panoramic OCTA OS before treatment at presentation shows a normal FAZ and a normal retinal capillary plexus from superficial to avascular area. Choroidal vasculature shows an area of large flow void and masking of the normal choroidal architecture pattern at the level of the RPE and Bruch membrane, suggesting choriocapillaris hypoperfusion (D).

Case No. 5

A 29-year-old man presented with decreased visual acuity OS lasting 1 month. His BCVA was 6/12 OS. A subretinal yellowish scar at the fovea was noted on fundus examination (Figure 5). SD-OCT showed a normal foveal contour, an altered photoreceptor layer, a small pigment epithelial detachment (PED), and subfoveal and juxtafoveal scarring, with central foveal thickness measuring 188 μm OS. FA revealed an altered FAZ and a hypofluorescent area in the foveal and juxtafoveal areas OS in early phase, which became hyperfluorescent in late phase, suggesting active choroiditis.

Panoramic OCTA with a 12-x-9-mm field of view showed a normal FAZ OS and a normal retinal capillary plexus from superficial to avascular area. Choroidal vasculature showed an area of large flow void and masking of the normal choroidal architecture pattern at the level of the retinal pigment epithelium (RPE) and Bruch membrane, suggesting choriocapillaris hypoperfusion.

The patient was treated with a course of intravenous

methylprednisolone for 3 days under physician supervision. He was also given a tapering course of oral steroids and was seen again 1 month later. His BCVA after treatment was 6/9 OS. A decrease in the size of the subretinal yellowish scar at the fovea was noted on fundus examination (Figure 6). SD-OCT showed a normal foveal contour OS, an altered photoreceptor layer, a small PED, subfoveal and juxtafoveal scarring, and central foveal thickness measuring 188 μm .

Panoramic OCTA with a 12-x-9-mm field of view showed a normal FAZ OS and normal retinal capillary plexus from superficial to avascular area. Choroidal vasculature now showed a decreased area of large flow void and unmasking of the normal small and large choroidal architecture pattern at the level of RPE-Bruch membrane, which suggested choriocapillaris reperfusion.

DISCUSSION

FA is considered the gold standard of imaging and is widely used in the diagnosis and management of a variety of ocular disorders.⁸⁻¹¹ FA provides information on the retinal vasculature, limited only to the superficial capillary plexus, and it lacks penetration to the choroid, thus providing no details of the choroidal vasculature.⁴ Indocyanine green angiography (ICGA) complements FA because it has

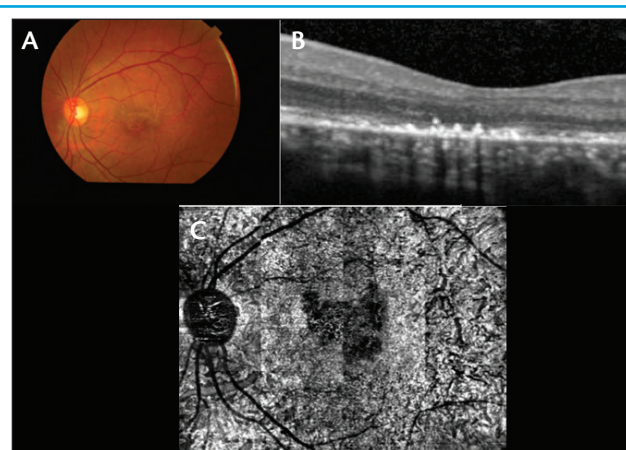


Figure 6. Fundus examination OS, after treatment shows a decrease in the size of the subretinal yellowish scar at the fovea (A). SD-OCT OS after treatment shows a normal foveal contour OS, an altered photoreceptor layer, a small PED, subfoveal and juxtafoveal scarring, and CFT measuring 188 μm (B). 12-x-9-mm panoramic OCTA OS after treatment shows a normal FAZ and normal retinal capillary plexus from superficial to avascular area. Choroidal vasculature now shows a decreased area of large flow void and unmasking of the normal small and large choroidal architecture pattern at the level of RPE-Bruch membrane, which suggests choriocapillaris reperfusion (C).

“ With the advent of panoramic imaging, OCTA can now mimic the findings of FA and replicate these on each follow-up exam noninvasively.

the ability to penetrate the choroid and it shows details of choroidal vascular pathologies.

Conventional dye-based angiography, including FA and ICGA, has some disadvantages; it is invasive, it requires intravenous dye injections, and it can cause side effects including extravasation, nausea, vasovagal reaction, and anaphylaxis. Conventional angiography also carries systemic risks, and it is expensive, time-consuming, and resource-intensive. Additionally, FA is contraindicated in pregnant women, in children, and in patients with renal or cardiac disorders. Repeatability is a major concern because of the invasive nature of injection-based angiography; hence, follow-up examination is difficult.¹²⁻¹⁷

OCTA is a revolutionary imaging modality that can detect retinal and choroidal blood flow compromise before the appearance of clinically meaningful changes. OCTA enables imaging of the retinal and choroidal vascular structure by detecting the reflectance phase and amplitude variation of blood flow over time to distinguish vessels from static tissue.^{18,19} It has thus provided us with new insights to better understand and manage retinal and choroidal pathologies.

With the advent of panoramic imaging, OCTA can now mimic the findings of FA and replicate these on each follow-up exam noninvasively. Although OCTA surpasses certain limitations of conventional angiography, this imaging modality is still in its infancy, and there is room for technical refinement. During the process of image acquisition, artifacts can occur due to eye movement, tremor, circadian rhythm, breathing, and image processing. These limitations should diminish as the technology is refined.

A PLACE FOR PANORAMIC OCTA?

Panoramic OCTA imaging is a unique tool that can replicate the findings of conventional angiography noninvasively. Panoramic OCTA can even replace FA and ICGA in certain

situations, such as in patients with contraindications to dye injections or side effects from previous examinations, and for follow-up examinations. Because it is a nascent technology, experience is still limited.

Prospective, longitudinal studies with larger cohorts are required to validate the accuracy of results and reproducibility of data generated to date. In the near future, with advances in medical engineering and further upgrades to software and technology, we hope to benefit from imaging software that can provide images with high resolution and much larger fields of view. Nonetheless, panoramic OCTA is certainly a promising imaging modality that is likely to play a part in the future of retinal imaging. ■

1. Shouhly SS, Kozak I. Selective and complementary use of optical coherence tomography and fluorescein angiography in retinal practice. *Eye Vis (Lond)*. 2016;3:26.
2. Nagpal M, Singh SS. OCT angiography in retinal and choroidal diseases. *Retina Today*. 2016;11(8):57-64.
3. Ghasemi Falavarjani K, Al-Sheikh M, Darvizeh F, et al. Retinal vessel calibre measurements by optical coherence tomography angiography [published online ahead of print November 16, 2016]. *Br J Ophthalmol*.
4. Spaide RF, Fujimoto JG, Waheed NK. Image artifacts in optical coherence tomography angiography. *Retina*. 2015;35(11):2163-2180.
5. Moulton EM, Waheed NK, Novais EA, et al. Swept-source optical coherence tomography angiography reveals choriocapillaris alterations in eyes with nascent geographic atrophy and drusen-associated geographic atrophy. *Retina*. 2016;36 (Suppl 1):S2-S11.
6. Zhang Q, Wang RK, Chen CL, et al. Swept source optical coherence tomography angiography of neovascular macular telangiectasia type 2. *Retina*. 2015;35(11):2285-2299.
7. Roisman L, Zhang Q, Wang RK, et al. Optical coherence tomography angiography of asymptomatic neovascularization in intermediate age-related macular degeneration. *Ophthalmology*. 2016;123(6):1309-1319.
8. Lumbroso B, Huang D, Fujimoto JG, Rispoli M, Jia Y. *Clinical guide to angio-OCT: non invasive, dyeless OCT angiography*. London: Jaypee Brothers Medical Publishers; 2015.
9. Sim DA, Keane PA, Zarranz-Venturaetal J, et al. The effects of macular ischemia on visual acuity in diabetic retinopathy. *Invest Ophthalmol Vis Sci*. 2013;54(3):2353-2360.
10. de Carlo TE, Romano A, Waheed NK, Duker JS. A review of optical coherence tomography angiography (OCTA). *Int J Retina Vitreous*. 2015;1:5.
11. de Carlo TE, Bonini Filho MA, Chin AT, et al. Spectral-domain optical coherence tomography angiography of choroidal neovascularization. *Ophthalmology*. 2015;122(6):1228-1238.
12. Garcia JM, Lima TT, Louzada RN, Rassi AT, Isaac DL, Avila M. Diabetic macular ischemia diagnosis: comparison between optical coherence tomography angiography and fluorescein angiography. *J Ophthalmol*. 2016;2016:3989310.
13. Yu S, Lu J, Cao D, et al. The role of optical coherence tomography angiography in fundus vascular abnormalities. *BMC Ophthalmol*. 2016;16:107.
14. Lipson BK, Yannuzzi LA. Complications of intravenous fluorescein injections. *Int Ophthalmol Clin*. 1989;29(3):200-205.
15. Pacurariu RI. Low incidence of side effects following intravenous fluorescein angiography. *Ann Ophthalmol*. 1982;14(1):32-36.
16. Lopez-Saez MP, Ordoqui E, Tornero P, et al. Fluorescein-induced allergic reaction. *Ann Allergy Asthma Immunol*. 1998;81(5 Pt 1):428-430.
17. Stanga PE, Lim JJ, Hamilton P. Indocyanine green angiography in chorioretinal diseases: indications and interpretation: an evidence-based update. *Ophthalmology*. 2003;110(1):15-21.
18. Jia Y, Bailey ST, Wilson DJ, et al. Quantitative optical coherence tomography angiography of choroidal neovascularization in age-related macular degeneration. *Ophthalmology*. 2014;121(7):1435-1444.
19. Jia Y, Tan O, Tokayer J, et al. Split-spectrum amplitude-decorrelation angiography with optical coherence tomography. *Opt Express*. 2012;20(4):4710-4725.

Rakesh Juneja, MS

- vitreoretinal fellow at the Retina Foundation in Ahmedabad, India
- financial interest: none acknowledged
- dr_rakeshjunaja555@yahoo.com

Manish Nagpal, MS, DO, FRCS(Edin)

- vitreoretinal consultant at the Retina Foundation in Ahmedabad, India
- financial disclosure: consultant to Nidek
- member of the *Retina Today* editorial advisory board
- drmanishnagpal@yahoo.com